

# RadPhi-3: Small Language Models for Radiology

Mercy Prasanna Ranjit *Microsoft Research India*  
Shaury Srivastav *Microsoft Research India*  
Tanuja Ganu *Microsoft Research India*

MERANJIT@MICROSOFT.COM  
T-SSRIVASTAV@MICROSOFT.COM  
TAGANU@MICROSOFT.COM

## Abstract

LLM based copilot assistants are useful in everyday tasks. There is also a proliferation in the exploration of AI assistant use cases to support radiology workflows in a reliable manner. In this work, we present **RadPhi-3**, a Small Language Model instruction tuned from **Phi-3-mini-4k-instruct** with 3.8B parameters to assist with various tasks in radiology workflows. While impression summary generation has been the primary task which has been explored in prior works w.r.t radiology reports of Chest X-rays, we also explore other useful tasks like change summary generation comparing the current radiology report and its prior report, section extraction from radiology reports, tagging the reports with various pathologies and tubes, lines or devices present in them etc. In-addition, instruction tuning **RadPhi-3** involved learning from a credible knowledge source used by radiologists, Radiopaedia.org. **RadPhi-3** can be used both to give reliable answers for radiology related queries as well as perform useful tasks related to radiology reports. **RadPhi-3** achieves SOTA results on the RaLEs radiology report generation benchmark.

**Keywords:** small language models, instruction tuning, chest x-rays, radiology reports

**Data and Code Availability** We leverage publicly available data for training **RadPhi-3**. We use a combination of annotations from multiple datasets like Mimic-CXR (Johnson et al., 2019), Medical-Diff VQA (Hu et al., 2023), ChestImagenome (Wu et al., 2021) and CheXpert Plus (Chambon et al., 2024) datasets. The Medical-Diff VQA and ChestImagenome dataset annotations are derived from radiology reports pertaining to Chest X-rays of Mimic-CXR dataset. We are not making the code available at this point.

**Institutional Review Board (IRB)** Proposed use of public datasets was reviewed by home in-

stitution. Under policy, use of de-identified public datasets is classified as Not Human Subjects Research [per 45§46.102(e)(1)(ii), 45§46.102(e)(5)]. Guidance and data reflection questions are provided to researchers including considerations to support representativeness, transparency and intended use.

## 1. Introduction

**Language Models for Radiology** AI-enabled copilot assistants are becoming popular in every domain with the increasing capabilities of LLMs to perform different tasks via instruction tuning and RLHF (Ouyang et al., 2022). While general domain LLMs can generalize with reasonable performance to perform tasks specific to radiology reports using in-context learning with few shots (Liu et al., 2023a), they still lag behind on nuanced tasks like impression generation, which is the conclusion or summary of the report where the radiologist provides their most likely diagnosis based on the findings from the imaging study and long-tail label prediction (Zhang et al., 2023) unless sophisticated prompt engineering is involved as noted in earlier works (Ranjit et al., 2024). In addition, the privacy-preserving machine learning requirements of the medical domain necessitate specialized radiology models that do not attribute the model performance to an individual record. Given these requirements, specialized radiology models are still needed, and we can't yet completely rely on general domain LLMs for all radiology-specific tasks.

**Advantages of SLMs** The large size of LLMs are prohibitive for easy training and deployments. The **Phi** series of SLMs (Small Language Models) (Abdin et al., 2024) is designed to be highly capable and cost-effective, outperforming models of similar or larger sizes across various language, reasoning, coding, and math benchmarks. We use the **Phi-3-mini-4k-instruct** model to further instruction tune for radiology question answering and

radiology report related tasks. The small size of `Phi-3-mini-4k-instruct` makes it ideal for easy finetuning for specialised tasks and in-house deployments of models to meet the privacy requirements common in medical settings. The latest addition to the `Phi-3` series, `Phi-3.5-mini-4k-instruct` has multi-lingual support, which encourages direct finetuning for radiology specific tasks in different languages without translating the radiology reports to English.

**Radiology Report Tasks** Impression summarisation from radiology report findings is a key useful task which has been explored in many prior works. (Liu et al., 2024),(Liu et al., 2023b). However, there are other useful tasks pertaining to radiology reports like, comparison of radiology reports to its prior report to summarize the changes between them, say a pathology condition has changed or a new device is placed etc. Radiology report segmentation is another useful task that can help extract useful sections from a radiology report like extraction of findings, impressions and placement description of tubes and lines. Noise removal from radiology reports is another useful utility task that can aid radiologists in their day-to-day workflows. We finetune `Phi-3-mini-4k-instruct` in a single stage setup for these tasks.

## Key Contributions

1. We finetune `Phi-3-mini-4k-instruct` SLM for radiology question answering using Radiopaedia articles<sup>1</sup> across fifteen systems and radiology report tasks pertaining to Chest X-rays. The resulting model `RadPhi-3` outperforms `RadPhi-2` (Ranjit et al., 2024) in radiology question answering and shows significant improvement in semantic tasks like radiology natural language inference and sentence similarity.
2. We introduce two new radiology report related tasks in addition to the tasks defined in the `RadPhi-2` work: radiology report segmentation to extract different sections of a radiology report and temporal change summary task to generate change summary of medical observations and support devices given the current report and prior report as inputs.
3. We benchmark `RadPhi-3` on various tasks and benchmarks: RaLEs (Chaves et al., 2023),

1. <https://radiopaedia.org/articles>

Mimic-CXR (Johnson et al., 2019) and CheXpert Plus (Chambon et al., 2024) for impression prediction, Radgraph2 (Dejl et al., 2024) for temporal change summary prediction, Medical diff VQA (Hu et al., 2023) for question answering comprehension, RADNLI (Miura et al., 2021) and MEDNLI (Shivade, 2017) for natural language inference, and CheXpert Plus (Chambon et al., 2024) for the radiology report segmentation task. We also benchmark `RadPhi-3` on a downstream task of multi-label classification of pathologies using Spanish radiology reports from the Padchest dataset (Bustos et al., 2019).

## 2. Related Work

**Instruction tuning for radiology** The work ‘Rad-Phi2: Instruction Tuning Phi2 for Radiology’ (Ranjit et al., 2024) was the first to explore instruction tuning for tasks pertaining to radiology report related workflows. They performed instruction tuning of the `Phi-2` SLM in two stages, first general domain instruction tuning followed by radiology specific instruction tuning and noted that two-stage instructing tuning is important for good performance on radiology report related tasks quoting that `Phi-2` was not an instruction-tuned model in the first place. They showed that radiology specific models are important for good performance on nuanced tasks like impression prediction and long tail label prediction from radiology reports. They also had two model versions, `RadPhi-2-Base` for Radiology Question Answering and `RadPhi-2` for radiology report related tasks. We extend the work of `RadPhi-2` with additional tasks and datasets and also update the instruction tuning to be based on `Phi-3-mini-4k-instruct`. We also do not use the general domain instruction tuning step used in `RadPhi-2` as `Phi-3-mini-4k-instruct` is already an instruction tuned model.

**Phi-3** `Phi-3-mini-4k-instruct` (Abdin et al., 2024) is one of the latest addition to the `Phi` SLM model series. The main difference from the `Phi2` model is that instruction tuning with direct preference optimization was added in the `Phi-3` version. We train using the `Phi3` version for our radiology specific instruction tuning.

**Temporal change summary** The paper ‘Rad-Graph2: Modeling Disease Progression in Radiology Reports via Hierarchical Information Extraction’ (Khanna et al., 2023) introduced the `Radgraph2`

dataset (Dejl et al., 2024) that has change tracking annotations w.r.t medical observations and support devices in radiology reports to help develop systems that track disease progression over time. We leverage these annotations to extract sections of radiology reports that capture the changes w.r.t medical observations or support devices and use it to benchmark RadPhi-3 on the new task of reporting temporal change summary w.r.t the current radiology report.

### 3. Methodology

In this section we explain the training datasets, finetuning approach, baselines and evaluation metrics we used for instruction tuning Phi-3-mini-4k-instruct for radiology specific tasks.

#### 3.1. Datasets

In this section we describe the datasets used for training RadPhi-3.

##### 3.1.1. RADIOLOGY QUESTION ANSWERING

The Radiology question answering dataset was constructed from Radiopaedia articles pertaining to 15 different systems and contains questions and answers related to radiological appearances of findings, differential diagnosis, assessing prognosis, and suggesting treatments etc. The dataset statistics is available in Table 12. It was constructed with the help of GPT-4 by sending the Radiopaedia articles as the context and instructing GPT-4 to construct QA pairs using the context. The prompt used for constructing the dataset is available in the appendix section E.

Question-answer pairs generated from the summary articles of Radiopaedia were reserved as the test set. We performed a radiologist evaluation of question-answer pairs generated from 82 randomly sampled articles from the train and test sets, stratified across systems, to check for hallucination of facts, instruction-following hallucinations, and the quality of questions and answers generated. Hallucination of facts refers to errors related to facts in the answers that were not present in the article. Instruction-following hallucinations refer to inadequate adherence to instructions while answering a question. Quality errors refer to question-answer pairs that are not very useful in a clinical setting. The evaluation results are available in Table 37. There

were zero factual hallucinations, five quality-related errors, and one instruction-following hallucination. The examples of these errors are available in Table 41, 42, and 43. As seen from these tables, the quality errors were primarily due to inadequate information in the Radiopaedia article.

##### 3.1.2. RADIOLOGY REPORT RELATED TASKS

There are useful tasks pertaining to radiology reports. Examples of such tasks include impression prediction from findings, abnormality and support devices label prediction, QA comprehension, extract findings/impression from a radiology report and cleanup of a noisy radiology report text. We extend the radiology report related instruction tuning dataset in the prior work RadPhi-2 (Ranjit et al., 2024) with additional tasks and datasets. This dataset is constructed by using the annotations of the public datasets defined in the data availability section and translating these annotations to an instruction format using the prompts defined in Table 31. We added impressions from the CheXpert Plus dataset for the impression prediction task.

The data split for all the tasks is based on Mimic-CXR’s official train, validation and test split as all of these datasets are derived from Mimic-CXR annotations. Tasks based on CheXpert Plus uses its official train and validation splits. The train, validation and test split for the different tasks is defined in Table 13.

We also added the below two new tasks, radiology report generation and temporal change summary to the instruction tuning dataset.

##### 3.1.3. RADIOLOGY REPORT SEGMENTATION

CheXpert Plus (Chambon et al., 2024) is a relatively new dataset with 187,711 radiology reports for Chest X-rays, each meticulously divided into subsections defined in Table 16. We introduce the radiology report segmentation task leveraging these annotations to segment the radiology reports into different report sections. We use the official train split for training and validation split for testing. The dataset statistics is available in Table 16. The prompt for translating the annotations from CheXpert Plus to the instruction tuning format is available in Table 31.

##### 3.1.4. TEMPORAL CHANGE SUMMARY

This task is defined as: Given a radiology report and its prior report, extract a change summary of medical

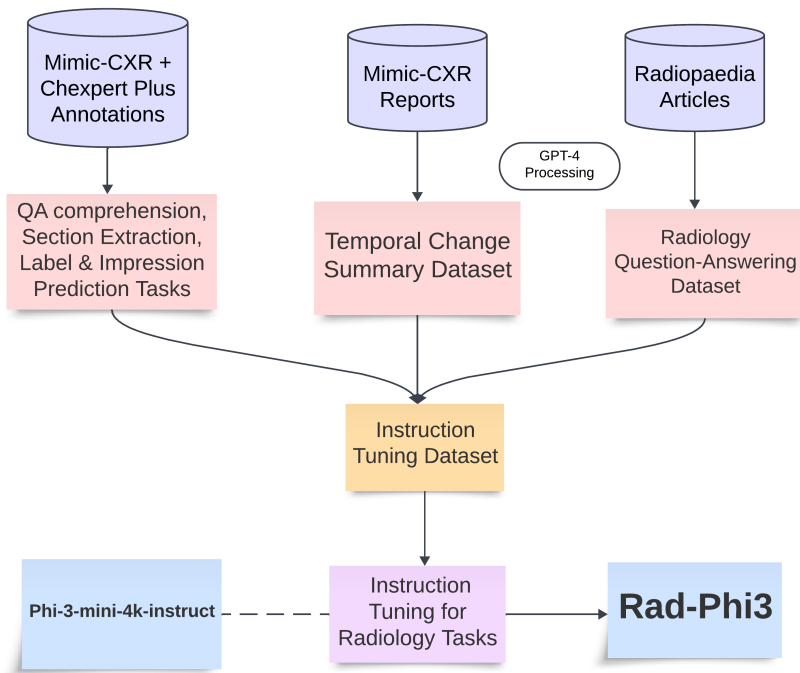


Figure 1: Training Workflow of RadPhi-3.

observations and support devices. This is extracted under 5 different categories (New, Resolved, Worsened, Stable and Improved) for medical conditions and 4 different categories (New, Removed, Changed and Unchanged) for support devices.

In addition, we also had a category for extracting the negative findings for medical conditions and recommendations for device adjustments. We use GPT-4 to extract the change summary using the prompt defined in the Appendix section E. The dataset statistics is available in Table 17.

We performed a radiologist evaluation of this dataset by sampling 50 examples from the test set to check for fact hallucinations, hallucinations of categories, and missed findings. Hallucinations of facts refer to errors related to facts in the answers that were not present in the current or prior report. Hallucinations of categories refer to errors where the change summary category (new, improved, worsened, resolved, etc.) was incorrectly assigned. Missed findings errors are related to the missed change mentions. The evaluation results are in Table 38. There were zero factual hallucinations. There were a few hallucinations with respect to the assignment of change categories, where GPT-4 incorrectly classified the change

category. An example of such is available in Table 40.

### 3.2. Fine-tuning Details

As shown in Figure 1, we create the instruction tuning dataset from Mimic-CXR reports and related annotations from the datasets described in section 3.1.2 for QA comprehension, label prediction, impression prediction, and extraction tasks.

We use GPT-4 processing to extract change summaries from Mimic-CXR reports with respect to medical observations and support devices as described in section 3.1.4 and question-answer pairs from radiology articles as described in section 3.1.1.

All of these together form the radiology instruction tuning dataset that is used to fine-tune RadPhi-3.

RadPhi-3 is fine-tuned from the Phi-3-mini-4k-instruct model checkpoint by continued fine-tuning for 3 epochs. We fine-tune using 4x NVIDIA A100 Tensor Core GPUs with 80GB VRAM using the Huggingface framework with Flash Attention 2, DeepSpeed Stage 3, and the paged\_adamw\_32bit optimizer. A global batch size of 128 was used for 3 epochs, as well as a base learning rate of 5e-5 and a warm-up ratio of 0.1.

### 3.3. Baselines

We use RadPhi-2 as our baseline model for both the Radiology QA task and the report related tasks. We also additionally measure the performance of Phi-3-mini-4k-instruct to check the radiology knowledge of a general domain model. We also compare with the existing SOTA approaches depending on the task.

### 3.4. Evaluation Metrics

#### 3.4.1. LEXICAL METRICS

We report the ROUGE-L (Lin, 2004), BLEU-4 (Papineni et al., 2002) and F1-score implementation of LlavaMed (Li et al., 2023) for the lexical metrics. For label prediction tasks, as its a multi-label classification, we use the f1-score implementation of scikit-learn. We report the macro average. <sup>2</sup>

#### 3.4.2. HALLUCINATION METRICS

We compute the AlignScore metric (Zha et al., 2023) for all the extraction tasks and the radiology question-answering related task to measure the factual consistency of the outputs w.r.t the inputs. This measures if the model generated text is factually consistent with the input context.

#### 3.4.3. CLINICAL METRICS

We report the F1-CheXbert(Smit et al., 2020), F1-RadGraph (Jain et al., 2021) for the clinical metrics.

F1-RadGraph is based on the RadGraph model (Jain et al., 2021) that parses the radiology report into graph of clinical entities (like anatomy and observations and relations) and the metric measures the overlap in clinical entities between the ground truth and candidate report. We use the Radgraph python package(v0.1.2) <sup>3</sup> which is an implementation of the Radgraph F1 metric based on rewards (Jain et al., 2021). We use the ‘partial’ reward level for computation of this metric.

F1-CheXbert(Smit et al., 2020) measures the micro-averaged F1 score of 14 disease mentions extracted from a generated summary in comparison to the ground truth. We also use the Chexbert python package(v0.0.2) for calculating the F1-Chexbert metric. <sup>4</sup>

2. [https://scikit-learn.org/stable/modules/generated/sklearn.metrics.f1\\_score.html](https://scikit-learn.org/stable/modules/generated/sklearn.metrics.f1_score.html)

3. <https://pypi.org/project/radgraph/>

4. <https://pypi.org/project/f1chexbert/>

We derive bootstrap confidence intervals for our evaluations by creating 10 resamples with replacement from the test dataset as our dataset is huge, where each resample is the size of the original test set. The temporal summary extraction and radiology report segmentation tasks were an exception to bootstrapping due to the low support for certain categories and we report stratified metrics for these two tasks.

## 4. Results

In this section we discuss the evaluation results of RadPhi-3 on various datasets and benchmarks.

### 4.1. Radiology Question Answering

The results of the radiology question answering task evaluation on the test set of Radiopaedia summary articles is available in Table 1 and the stratified metrics by system in Table 18 .

The stratified metrics by system shows that RadPhi3-Instruct performs better than GPT-4 on all the systems and by a large margin on systems like Hepatobiliary, Urogenital, Breast, Musculoskeletal, Forensic and Gastrointestinal. It is also better than RadPhi2-Instruct on all the systems. It is interesting to note that Phi-3-mini-4k-instruct has the highest recall value pointing to its reasonably good radiology knowledge and has comparable metrics to GPT-4 on many systems as seen from the stratified metrics.

An example prediction from RadPhi3-Instruct, Phi-3-mini-4k-instruct and GPT-4 models is available on Table 21. We see that RadPhi3-Instruct is able to give clear, concise and factually correct answer to the question.

### 4.2. Impression Prediction

The results of the evaluation of the impression prediction task from the findings of a radiology report on the test set of Mimic-CXR is available in Table 2. Both RadPhi-2 and RadPhi-3 is better than Impression GPT (Ma et al., 2024) and establishes SOTA performance. We note that we pre-processed the impressions with GPT-4 to remove noise using the prompt we defined for the cleanup radiology text task in Table 31.

The metrics of the impression prediction task on the CheXpert Plus validation dataset is available in

Table 1: Radiology Question Answering Metrics on Radiopaedia Summary Articles.

Models	F1-Score	Precision	Recall	RougeL
Phi-3-mini-4k-instruct	32.91 [31.3, 34.93]	21.01 [19.33, 22.47]	<b>76.66</b> [73.54, 79.55]	11.39 [9.96, 12.55]
GPT-4	33.98 [31.09, 37.02]	28.68 [26.24, 31.69]	42.07 [37.33, 46.96]	23.68 [21.87, 26.35]
RadPhi-2	38.98 [35.72, 42.83]	40.97 [37.35, 46.75]	37.3 [32.85, 41.95]	27.01 [23.96, 29.82]
RadPhi-3	<b>40.33</b> [36.56, 44.14]	<b>42.71</b> [37.71, 46.16]	38.39 [34.92, 43.02]	<b>28.39</b> [24.98, 31.54]

RadPhi-3 is better than RadPhi-2 on all the metrics. Phi-3-mini-4k-instruct has a good recall value indicating the reasonable radiology knowledge of the general domain model.

Table 2: Impression Prediction Metrics on Mimic-CXR Test Set

Models	F1 Chexbert	F1 RadGraph	RougeL	F1-Score
Phi-3-mini-4k-instruct	50.29 [50.19, 51.21]	12.80	12.18 [12.01, 12.48]	24.11 [23.56, 24.5]
GPT-4 (Impression-GPT)	64.9		46.0	
RadPhi-2	<b>67.87</b> [66.95, 68.61]	<b>43.06</b>	<b>49.74</b> [49.09, 50.47]	<b>59.66</b> [59.15, 60.55]
RadPhi-3	66.66 [65.64, 67.48]	41.74	48.33 [47.56, 48.91]	58.52 [57.66, 59.47]

RadPhi-3 performs comparable to RadPhi-2 on all the metrics and both are better than Impression GPT.

Table 3: Impression Prediction Metrics on ChexPert Plus Validation Set

Models	F1 Chexbert	F1 RadGraph	RougeL	F1-Score
Phi-3-mini-4k-instruct	60.61 [56.22, 67.59]	24.92	19.87 [18.09, 21.74]	33.08 [31.32, 34.97]
RadPhi-2	59.4 [52.98, 61.59]	33.65	40.72 [33.95, 44.95]	49.97 [44.71, 54.35]
RadPhi-3	<b>64.02</b> [58.69, 68.92]	<b>47.84</b>	<b>47.51</b> [44.81, 49.27]	<b>57.89</b> [53.45, 59.35]

RadPhi-3 is better than RadPhi-2 in all the metrics.

Table 4: Abnormality and Support Devices Label Metrics - ChestImagenome Labels

Task	Metrics	Phi-3-mini-4k-instruct	RadPhi-2	RadPhi-3
Tubes/Lines/Devices Labels	F1-Score	63.05 [62.72, 63.35]	<b>95.54</b> [95.16, 95.2]	95.16 [94.54, 95.61]
	Recall	61.43 [61.17, 61.71]	<b>95.82</b> [95.43, 95.51]	95.49 [94.93, 95.93]
	Precision	71.64 [71.01, 71.95]	<b>95.49</b> [95.12, 95.15]	95.07 [94.43, 95.54]
Abnormality Labels	F1-Score	76.72 [76.08, 77.2]	<b>94.68</b> [94.57, 94.87]	93.36 [93.04, 93.67]
	Recall	76.4 [75.77, 76.82]	<b>94.88</b> [94.82, 95.0]	93.89 [93.49, 94.12]
	Precision	78.86 [78.18, 79.48]	<b>95.54</b> [95.4, 95.79]	93.98 [93.59, 94.34]

RadPhi-2 is slightly better than RadPhi-3. We report the macro F1 score.

Table 5: QA Comprehension, Findings/Impression Extraction and Clean Radiology Text Task Metrics

Task	Metrics	Phi-3-mini-4k-instruct	RadPhi2-Instruct	RadPhi-3
QA Comprehension	F1-Score	13.07 [12.78, 13.24]	<b>98.1</b> [97.88, 98.25]	96.98 [96.88, 97.26]
	Precision	7.13 [7.03, 7.24]	<b>97.95</b> [97.84, 98.15]	97.05 [96.88, 97.38]
	Recall	78.04 [77.45, 78.59]	<b>98.25</b> [98.13, 98.44]	96.91 [96.71, 97.21]
	RougeL	2.96 [2.89, 2.98]	<b>97.61</b> [97.45, 97.8]	96.18 [95.87, 96.32]
Cleanup Radiology Text	F1-Score	70.78 [70.49, 71.23]	92.06 [91.97, 92.16]	<b>92.13</b> [91.91, 92.38]
	BLEU-4	17.43 [17.08, 17.67]	73.23 [72.99, 73.47]	<b>73.29</b> [72.8, 73.74]
	RougeL	36.32 [35.81, 36.61]	86.82 [86.63, 86.95]	<b>86.95</b> [86.77, 87.14]
	AlignScore	61.22 [60.82, 61.68]	<b>93.97</b> [93.81, 94.12]	93.61 [93.5, 93.89]
Extraction	F1-Score	73.93 [73.7, 74.12]	<b>91.85</b> [91.74, 91.99]	91.83 [91.55, 91.94]
	BLEU-4	38.19 [37.9, 38.53]	72.67 [71.99, 73.07]	<b>72.72</b> [72.49, 73.21]
	RougeL	62.13 [61.85, 62.43]	<b>86.55</b> [86.22, 86.83]	86.44 [86.3, 86.73]
	AlignScore	59.83 [59.12, 60.44]	<b>93.75</b> [93.36, 94.02]	93.35 [93.02, 93.57]

RadPhi-2 performs comparable to RadPhi-3 on all the metrics.

Table 6: NLI Metrics (RADLI + MEDNLI)

Model	F1-Score	Precision	Recall
Phi-3-mini-3k-instruct	22.29 [21.59, 30.88]	42.36 [40.45, 58.95]	30.04 [29.61, 40.93]
RadPhi-2	0.17 [0.02, 0.31]	50.0 [5.62, 50.0]	0.09 [0.01, 0.16]
RadPhi-3	<b>83.89</b> [82.3, 84.56]	<b>83.66</b> [82.01, 84.33]	<b>84.55</b> [83.05, 85.27]

RadPhi-3 performs significantly better than RadPhi-2 on NLI task.

Table 3. An example prediction for the Impression prediction task is available in Table 23 in the Appendix section.

### 4.3. Abnormality and Support Devices Prediction

The performance metrics of the abnormality and support devices label prediction from the radiology reports is available in Table 4. We see that RadPhi-3 has comparable metrics to RadPhi-2 in both the abnormality and support devices label prediction tasks. Example predictions for the tubes, lines and devices prediction and abnormality labels prediction is available in Table 26 and Table 19 respectively.

### 4.4. QA Comprehension, Cleanup Radiology Text and Findings/Impression Extraction Tasks

The performance metrics of QA Comprehension and other utility tasks like noise removal from a radiology text and extracting a clean set of findings/impression from a radiology report is available in Table 5. We see that RadPhi-3 has comparable metrics to RadPhi-2 in the findings/impression extraction and cleanup radiology text tasks and RadPhi-2 is slightly better on the QA comprehension task. We also note that the general domain Phi3-mini-4k-instruct model has lower performance on these tasks, particularly on the QA comprehension task. We also note the Align Score metric is high for these tasks indicating the factual consistency of the outputs to the inputs.

Example results for the QA comprehension task is available in Table 20, extract findings/impression task is available in Table 25 and cleanup radiology text task is available in Table 24.

### 4.5. Natural Language Inference

The performance metrics of Natural Language Inference on the MEDNLI and RADNLI datasets is available in Table 6. RadPhi-2 has poor performance on semantic tasks as it went through minimal general domain instruction tuning. RadPhi-3 shows significant

improvement on this task over RadPhi-2. Sample results from the RadPhi-3 is available in Table 27.

### 4.6. Radiology Report Segmentation

The performance of RadPhi-3 on the CheXpert Plus (Chambon et al., 2024) validation dataset to divide the radiology report text into different sections (defined in Table 16) is available in Table 7. We note that RadPhi-3 performs very well on the radiology report section segmentation task, sample results are available in Table 29. The Align Score for the extraction of all the report sections is very high indicating the factual consistency of the outputs to the inputs.

### 4.7. Temporal Change Summary

The performance metrics of the Temporal Change Summary Task to summarise the changes in the medical conditions and support devices comparing the current radiology report and its prior is presented in Table 8. As seen from the table, the best performing change category is ‘Stable’ for both the medical conditions and support devices. The least performing categories for support devices are the ‘Changed’ and ‘Recommendations’ categories which reports the changes in the placement of devices and related recommendations. This is due to the fact that we have very less support for cases that report the changes in the placement of devices in the dataset. Sample model predictions for the temporal change summary task is available in Table 30.

### 4.8. Generalization Testing

We also performed generalization testing of Rad-Phi2-Instruct and Rad-Phi3-Instruct models using some examples of tasks the models have not seen before. We have the following observations:

**RadQA Dataset** We performed a variant of the QA comprehension task using the RadQA (Soni and Roberts, 2022) dataset. In this task, the model was asked to extract the part of the radiology report that

can answer the question. The reports in this dataset pertain to various imaging modalities and anatomical systems. We found that `Rad-Phi3-Instruct` can generalize better than `Rad-Phi2-Instruct`. Example predictions from both models are available in Table 34.

**Sentence Similarity** We used the MS-CXR-T (Bannur et al., 2023) dataset to test the generalization performance of `Rad-Phi3-Instruct` and `Rad-Phi2-Instruct` on a semantic task. The task is to assess whether two sentences are describing the same meaning (paraphrase) or different meanings (different) given a change summary. We found that `Rad-Phi2-Instruct` is unable to perform this task at all, while `Rad-Phi3-Instruct` and the base model `Phi3-mini-4k-instruct` were able to perform it. Example predictions are available in Table 32 and Table 33.

**Tubes and Lines Placement** In this task, the models were asked to describe the placement of devices mentioned in the report. Although this task was new to the models, both `Rad-Phi2-Instruct` and `Rad-Phi3-Instruct` were able to perform it successfully, while the base model `Phi3-mini-4k-instruct` was not able to perform this task. Example predictions are available in Table 35.

## 4.9. NLG Benchmarks

### 4.9.1. RALEs BENCHMARK

RaLEs is a benchmark group of datasets for natural language understanding and generation in radiology. We focus only on the natural language generation task from this benchmark to predict the Impressions section of a radiology report given the Findings, using the MEDIQA 2021 (Ben Abacha et al., 2021) and BioNLP 2023 (Delbrouck et al., 2023) datasets. BioNLP 2023 dataset contains computed tomography reports and magnetic resonance imaging examinations of head, chest, abdomen, spine and sinuses. This dataset is good to benchmark the impression prediction task for regions other than Chest and modalities other than X-rays. MEDIQA 2021 contains radiology reports of only Chest X-rays from the Mimic-CXR dataset. The statistics of the datasets in the RaLEs benchmark is available in Table 14.

**NLG Score** We compute the NLG (Natural Language Generation) score for the RaLEs benchmark (Chaves et al., 2023). NLG score is the average of

the ROUGE-L and RadGraph metrics across both the datasets for comparison with the leader board.

We note that `RadPhi-3` achieves SOTA performance on the RaLEs benchmark surpassing the existing SOTA results by a large margin in both the clinical and lexical metrics for the BIONLP-2023 dataset. We also note that as `RadPhi-3` was trained on paraphrased versions of impressions of the MIMIC-CXR dataset, we preprocess the impression sections of the MEDIQA-2021 dataset which is also MIMIC-CXR based using the cleanup radiology text prompt defined in Table 31. The metrics are available in Table 9.

### 4.9.2. TEMPORAL RADIOLOGY REPORT SUMMARY

We leverage the Radgraph2 dataset (Khanna et al., 2023) annotations to extract the lines from the radiology report that mentions a change about a medical condition or a support device. The metrics are available in Table 11. As seen from the result, the model is able to extract the change mentions of medical observations and support devices reasonably well for all categories except for the resolved category of medical observations which has very less support as seen from the dataset statistics of the RadGraph2 dataset in Table 15. Sample predictions of this task is available in Table 28.

### 4.9.3. PADCHEST BENCHMARK

We use the Padchest (Bustos et al., 2019) dataset annotations which contains radiology reports in the Spanish language as a downstream task of `RadPhi-3` to predict the abnormality labels associated with the Spanish reports. We use a prompt in the Spanish language defined in Table 31 for this task. The metrics in Table 10 shows that `RadPhi-3`'s performance on this task is very good. A sample prediction on Spanish reports is available in Table 22.

## 5. Discussion

In this work, we presented `RadPhi-3`, an SLM with 3.8B parameters finetuned from `Phi-3-mini-4k-instruct` for radiology specific tasks. The instruction tuning involved knowledge intensive tasks like radiology question answering and also ten different tasks related to radiology reports. Unlike `RadPhi-2`, which was finetuned from `Phi-2` and was preceded with a general domain instruction tuning and used a special token based



input format, RadPhi-3 was directly finetuned from Phi-3-mini-4k-instruct using the default instruction format. RadPhi-3 shows significant improvement over RadPhi-2 on radiology question answering for all the systems and natural language inference tasks while being on-par on rest of the tasks.

SLMs like RadPhi-3 can be easily trained for more nuanced tasks in Radiology domain where general domain LLMs falls short unless prompted with carefully curated dynamic examples (Ma et al., 2024). Example of such tasks include long tail label prediction (Padchest radiology reports is mapped to 347 abnormality categories), impression prediction and radiology question answering which requires deep knowledge of the domain. This was also evident from the the stratified metrics of the radiology question answering task available in Table 18 where we note that GPT-4 falls short in radiology knowledge when compared to RadPhi-3 on systems like Hepatobiliary, Urogenital, Breast, Musculoskeletal, Forensic and Gastrointestinal.

We presented two new tasks in this work, Radiology Report Segmentation to extract different sections from a radiology report and the Temporal Change Summary task to summarize the changes of medical observations and support devices from a radiology report and its prior report. We also bench marked RadPhi-3’s performance on ten different tasks like Impression Prediction, Abnormality Label Prediction, Tubes, Lines and Device Label Prediction, Temporal Summary Extraction, QA comprehension, Findings/Impression Extraction, Cleanup Radiology Text, Natural Language Inference, Radiology Report Segmentation and Abnormality Label Prediction from Spanish reports.

RadPhi-3 achieves SOTA performance on the RaLEs benchmark for generative tasks with significant improvement for the BioNLP 2023 dataset which contains radiology reports from systems other than Chest and modalities other than X-rays showing that the model is able to generalize well and can be extended to other report types.

**Limitations and Future Work** The current work did not explore the advantages of a radiology instruction-tuned SLM in a multimodal setting especially for finetuning in a limited dataset setting and low rank adaptation settings where we anticipate it would add more value. The future work can explore in this direction. RadPhi-3 was also instruction

tuned only using radiology reports of Chest X-rays, future work can extend this across systems, modalities, languages and additional tasks.

## Acknowledgments

We thank the Radiopaedia team for their data and resources, which have advanced our radiology research. Special thanks to Dr. Kondaru Vishnu Vardhan Reddy from Manipal Hospitals Radiology Group, Bengaluru, and Dr.Sudhir Kumar Yadav from King George’s Medical University, Lucknow, for evaluating our datasets and model predictions and providing valuable feedback.

## References

Marah Abdin, Jyoti Aneja, Hany Awadalla, Ahmed Awadallah, Ammar Ahmad Awan, Nguyen Bach, Amit Bahree, Arash Bakhtiari, Jianmin Bao, Harkirat Behl, Alon Benhaim, Misha Bilenko, Johan Bjorck, Sébastien Bubeck, Martin Cai, Qin Cai, Vishrav Chaudhary, Dong Chen, Dongdong Chen, Weizhu Chen, Yen-Chun Chen, Yi-Ling Chen, Hao Cheng, Parul Chopra, Xiyang Dai, Matthew Dixon, Ronen Eldan, Victor Fragoso, Jianfeng Gao, Mei Gao, Min Gao, Amit Garg, Allie Del Giorno, Abhishek Goswami, Suriya Gunasekar, Emman Haider, Junheng Hao, Russell J. Hewett, Wenxiang Hu, Jamie Huynh, Dan Iter, Sam Ade Jacobs, Mojan Javaheripi, Xin Jin, Nikos Karampatziakis, Piero Kauffmann, Mahoud Khademi, Dongwoo Kim, Young Jin Kim, Lev Kurilenko, James R. Lee, Yin Tat Lee, Yanzhi Li, Yunsheng Li, Chen Liang, Lars Liden, Xihui Lin, Zeqi Lin, Ce Liu, Liyuan Liu, Mengchen Liu, Weishung Liu, Xiaodong Liu, Chong Luo, Piyush Madan, Ali Mahmoudzadeh, David Majercak, Matt Mazzola, Caio César Teodoro Mendes, Arindam Mitra, Hardik Modi, Anh Nguyen, Brandon Norick, Barun Patra, Daniel Perez-Becker, Thomas Portet, Reid Pryzant, Heyang Qin, Marko Radmilac, Liliang Ren, Gustavo de Rosa, Corby Rosset, Sambudha Roy, Olatunji Ruwase, Olli Saarikivi, Amin Saied, Adil Salim, Michael Santacroce, Shital Shah, Ning Shang, Hiteshi Sharma, Yelong Shen, Swadheen Shukla, Xia Song, Masahiro Tanaka, Andrea Tupini, Praneetha Vaddamanu, Chunyu Wang, Guanhua Wang, Lijuan Wang, Shuohang Wang, Xin Wang, Yu Wang, Rachel Ward, Wen Wen, Philipp Witte, Haiping

- Wu, Xiaoxia Wu, Michael Wyatt, Bin Xiao, Can Xu, Jiahang Xu, Weijian Xu, Jilong Xue, Sonali Yadav, Fan Yang, Jianwei Yang, Yifan Yang, Ziyi Yang, Donghan Yu, Lu Yuan, Chenruidong Zhang, Cyril Zhang, Jianwen Zhang, Li Lina Zhang, Yi Zhang, Yue Zhang, Yunan Zhang, and Xiren Zhou. Phi-3 technical report: A highly capable language model locally on your phone, 2024. URL <https://arxiv.org/abs/2404.14219>.
- Shruthi Bannur, Stephanie Hyland, Qianchu Liu, Fernando Pérez-García, Max Ilse, Daniel Coelho de Castro, Benedikt Boecking, Harshita Sharma, Kenza Bouzid, Anton Schwaighofer, Maria Teodora Wetscherek, Hannah Richardson, Tristan Naumann, Javier Alvarez Valle, and Ozan Oktay. MS-CXR-T: Learning to exploit temporal structure for biomedical vision-language processing, 2023.
- Asma Ben Abacha, Yassine Mrabet, Yuhao Zhang, Chaitanya Shivade, Curtis Langlotz, and Dina Demner-Fushman. Overview of the MEDIQA 2021 shared task on summarization in the medical domain. In Dina Demner-Fushman, Kevin Bretonnel Cohen, Sophia Ananiadou, and Junichi Tsujii, editors, *Proceedings of the 20th Workshop on Biomedical Language Processing*, pages 74–85, Online, June 2021. Association for Computational Linguistics. doi: 10.18653/v1/2021.bionlp-1.8. URL <https://aclanthology.org/2021.bionlp-1.8>.
- Aurelia Bustos, Antonio Pertusa, Jose-Maria Salinas, and Maria de la Iglesia-Vayá. Padchest: A large chest x-ray image dataset with multi-label annotated reports, 2019. URL <https://arxiv.org/abs/1901.07441>.
- Pierre Chambon, Jean-Benoit Delbrouck, Thomas Sounack, Shih-Cheng Huang, Zhihong Chen, Maya Varma, Steven QH Truong, Chu The Chuong, and Curtis P. Langlotz. Chexpert plus: Augmenting a large chest x-ray dataset with text radiology reports, patient demographics and additional image formats, 2024. URL <https://arxiv.org/abs/2405.19538>.
- Juan Manuel Zambrano Chaves, Nandita Bhaskhar, Maayane Attias, Jean-Benoit Delbrouck, Daniel Rubin, Andreas Markus Loening, Curtis Langlotz, and Akshay S Chaudhari. RaLEs: a benchmark for radiology language evaluations. In *Thirty-seventh Conference on Neural Information Processing Systems Datasets and Benchmarks Track*, 2023. URL <https://openreview.net/forum?id=PWLGrvoqiR>.
- Adam Dejl, Sameer Khanna, Patricia Therese Pile, Kibo Yoon, Steven Q H Truong, Hanh Duong, Agustina Saenz, and Pranav Rajpurkar. RadGraph2: Tracking findings over time in radiology reports, 2024.
- Jean-Benoit Delbrouck, Maya Varma, Pierre Chambon, and Curtis Langlotz. Overview of the RadSum23 shared task on multi-modal and multi-anatomical radiology report summarization. In Dina Demner-fushman, Sophia Ananiadou, and Kevin Cohen, editors, *The 22nd Workshop on Biomedical Natural Language Processing and BioNLP Shared Tasks*, pages 478–482, Toronto, Canada, July 2023. Association for Computational Linguistics. doi: 10.18653/v1/2023.bionlp-1.45. URL <https://aclanthology.org/2023.bionlp-1.45>.
- Xinyue Hu, Lin Gu, Qiyuan An, Mengliang Zhang, Liangchen Liu, Kazuma Kobayashi, Tatsuya Harada, Ronald M. Summers, and Yingying Zhu. Expert knowledge-aware image difference graph representation learning for difference-aware medical visual question answering. In *Proceedings of the 29th ACM SIGKDD Conference on Knowledge Discovery and Data Mining, KDD '23*, page 4156–4165, New York, NY, USA, 2023. Association for Computing Machinery. ISBN 9798400701030. doi: 10.1145/3580305.3599819. URL <https://doi.org/10.1145/3580305.3599819>.
- Saahil Jain, Ashwin Agrawal, Adriel Saporta, Steven QH Truong, Du Nguyen Duong, Tan Bui, Pierre Chambon, Yuhao Zhang, Matthew P. Lungren, Andrew Y. Ng, Curtis P. Langlotz, and Pranav Rajpurkar. Radgraph: Extracting clinical entities and relations from radiology reports, 2021. URL <https://arxiv.org/abs/2106.14463>.
- Alistair E. W. Johnson, Tom J. Pollard, Seth J. Berkowitz, Nathaniel R. Greenbaum, Matthew P. Lungren, Chih-ying Deng, Roger G. Mark, and Steven Horng. Mimic-cxr, a de-identified publicly available database of chest radiographs with free-text reports. *Scientific Data*, 6(1):317, Dec 2019. ISSN 2052-4463. doi: 10.1038/s41597-019-0322-0. URL <https://doi.org/10.1038/s41597-019-0322-0>.

- Sameer Khanna, Adam Dejl, Kibo Yoon, Steven QH Truong, Hanh Duong, Agustina Saenz, and Pranav Rajpurkar. Radgraph2: Modeling disease progression in radiology reports via hierarchical information extraction. In Kaivalya Deshpande, Madalina Fiterau, Shalmali Joshi, Zachary Lipton, Rajesh Ranganath, Iñigo Urteaga, and Serene Yeung, editors, *Proceedings of the 8th Machine Learning for Healthcare Conference*, volume 219 of *Proceedings of Machine Learning Research*, pages 381–402. PMLR, 11–12 Aug 2023. URL <https://proceedings.mlr.press/v219/khanna23a.html>.
- Chunyuan Li, Cliff Wong, Sheng Zhang, Naoto Usuyama, Haotian Liu, Jianwei Yang, Tristan Naumann, Hoifung Poon, and Jianfeng Gao. Llava-med: Training a large language-and-vision assistant for biomedicine in one day, 2023. URL <https://arxiv.org/abs/2306.00890>.
- Chin-Yew Lin. ROUGE: A package for automatic evaluation of summaries. In *Text Summarization Branches Out*, pages 74–81, Barcelona, Spain, July 2004. Association for Computational Linguistics. URL <https://aclanthology.org/W04-1013>.
- Qianchu Liu, Stephanie Hyland, Shruthi Bannur, Kenza Bouzid, Daniel Castro, Maria Wetscherek, Robert Tinn, Harshita Sharma, Fernando Pérez-García, Anton Schwaighofer, Pranav Rajpurkar, Sameer Khanna, Hoifung Poon, Naoto Usuyama, Anja Thieme, Aditya Nori, Matthew Lungren, Ozan Oktay, and Javier Alvarez-Valle. Exploring the boundaries of GPT-4 in radiology. In Houda Bouamor, Juan Pino, and Kalika Bali, editors, *Proceedings of the 2023 Conference on Empirical Methods in Natural Language Processing*, pages 14414–14445, Singapore, December 2023a. Association for Computational Linguistics. doi: 10.18653/v1/2023.emnlp-main.891. URL <https://aclanthology.org/2023.emnlp-main.891>.
- Zhengliang Liu, Yiwei Li, Peng Shu, Aoxiao Zhong, Longtao Yang, Chao Ju, Zihao Wu, Chong Ma, Jie Luo, Cheng Chen, Sekeun Kim, Jiang Hu, Haixing Dai, Lin Zhao, Dajiang Zhu, Jun Liu, Wei Liu, Dinggang Shen, Tianming Liu, Quanzheng Li, and Xiang Li. Radiology-llama2: Best-in-class large language model for radiology, 2023b. URL <https://arxiv.org/abs/2309.06419>.
- Zhengliang Liu, Aoxiao Zhong, Yiwei Li, Longtao Yang, Chao Ju, Zihao Wu, Chong Ma, Peng Shu, Cheng Chen, Sekeun Kim, Haixing Dai, Lin Zhao, Lichao Sun, Dajiang Zhu, Jun Liu, Wei Liu, Dinggang Shen, Xiang Li, Quanzheng Li, and Tianming Liu. Radiology-gpt: A large language model for radiology, 2024. URL <https://arxiv.org/abs/2306.08666>.
- Chong Ma, Zihao Wu, Jiaqi Wang, Shaochen Xu, Yaonai Wei, Zhengliang Liu, Fang Zeng, Xi Jiang, Lei Guo, Xiaoyan Cai, Shu Zhang, Tuo Zhang, Dajiang Zhu, Dinggang Shen, Tianming Liu, and Xiang Li. An iterative optimizing framework for radiology report summarization with chatgpt. *IEEE Transactions on Artificial Intelligence*, 5(8): 4163–4175, August 2024. ISSN 2691-4581. doi: 10.1109/tai.2024.3364586. URL <http://dx.doi.org/10.1109/TAI.2024.3364586>.
- Yasuhide Miura, Yuhao Zhang, Emily Tsai, Curtis Langlotz, and Dan Jurafsky. RadNLI: A natural language inference dataset for the radiology domain, 2021.
- Long Ouyang, Jeff Wu, Xu Jiang, Diogo Almeida, Carroll L. Wainwright, Pamela Mishkin, Chong Zhang, Sandhini Agarwal, Katarina Slama, Alex Ray, John Schulman, Jacob Hilton, Fraser Kelton, Luke Miller, Maddie Simens, Amanda Askell, Peter Welinder, Paul Christiano, Jan Leike, and Ryan Lowe. Training language models to follow instructions with human feedback, 2022. URL <https://arxiv.org/abs/2203.02155>.
- Kishore Papineni, Salim Roukos, Todd Ward, and Wei-Jing Zhu. Bleu: a method for automatic evaluation of machine translation. In Pierre Isabelle, Eugene Charniak, and Dekang Lin, editors, *Proceedings of the 40th Annual Meeting of the Association for Computational Linguistics*, pages 311–318, Philadelphia, Pennsylvania, USA, July 2002. Association for Computational Linguistics. doi: 10.3115/1073083.1073135. URL <https://aclanthology.org/P02-1040>.
- Mercy Ranjit, Gopinath Ganapathy, Shaury Srivastav, Srujana Oruganti, and Tanuja Ganu. Rad-Phi2: Instruction tuning phi2 for radiology. *Advances in Artificial Intelligence and Machine Learning*, 04(02):2302–2323, 2024.
- Chaitanya Shivade. MedNLI — a natural language inference dataset for the clinical domain, 2017.

Akshay Smit, Saahil Jain, Pranav Rajpurkar, Anuj Pareek, Andrew Ng, and Matthew Lungren. Combining automatic labelers and expert annotations for accurate radiology report labeling using BERT. In Bonnie Webber, Trevor Cohn, Yulan He, and Yang Liu, editors, *Proceedings of the 2020 Conference on Empirical Methods in Natural Language Processing (EMNLP)*, pages 1500–1519, Online, November 2020. Association for Computational Linguistics. doi: 10.18653/v1/2020.emnlp-main.117. URL <https://aclanthology.org/2020.emnlp-main.117>.

Sarvesh Soni and Kirk Roberts. RadQA: A question answering dataset to improve comprehension of radiology reports, 2022.

Joy Wu, Nkechinyere Agu, Ismini Lourentzou, Arjun Sharma, Joseph Paguio, Jasper Seth Yao, Edward Christopher Dee, William Mitchell, Satyananda Kashyap, Andrea Giovannini, Leo Anthony Celi, Tanveer Syeda-Mahmood, and Mehdi Moradi. Chest ImaGenome dataset, 2021.

Yuheng Zha, Yichi Yang, Ruichen Li, and Zhiting Hu. Alignscore: Evaluating factual consistency with a unified alignment function, 2023. URL <https://arxiv.org/abs/2305.16739>.

Ruohong Zhang, Yau-Shian Wang, Yiming Yang, Donghan Yu, Tom Vu, and Likun Lei. Long-tailed extreme multi-label text classification by the retrieval of generated pseudo label descriptions. In Andreas Vlachos and Isabelle Augenstein, editors, *Findings of the Association for Computational Linguistics: EACL 2023*, pages 1092–1106, Dubrovnik, Croatia, May 2023. Association for Computational Linguistics. doi: 10.18653/v1/2023.findings-eacl.81. URL <https://aclanthology.org/2023.findings-eacl.81>.

## Appendix A. Evaluation Benchmarks

Table 7: Radiology Report Segmentation Metrics (CheXpert Plus sections)

Report Section	BLEU-4	RougeL	F1-Score	AlignScore
Clinical History	66.38	100.0	98.56	99.46
Comparisons	73.39	100.00	96.49	99.80
Technique	8.54	100.00	98.25	99.36
Procedure Comments	16.41	100.00	98.37	99.41
Impression	99.81	99.91	99.84	89.03
Findings	32.71	99.01	98.27	98.88
End Of Impression	4.78	98.72	97.57	99.31
Summary	83.03	100	99.61	99.69

RadPhi-3 performs very well on section extraction task.

Table 8: Temporal Change Summary Metrics (Mimic-CXR reports)

Change Category	Labels	BLEU-4	RougeL	F1-Score	Support
Medical conditions Change Summary	New	20.13	27.74	30.10	1243
	Resolved	10.44	17.62	18.79	840
	Stable	41.24	61.94	67.73	2564
	Improved	8.30	13.98	14.75	543
	Worsened	8.18	13.19	14.45	666
	Negatives	43.03	65.97	70.61	2374
Tubes and Lines Change Summary	New	16.73	19.32	20.10	754
	Removed	11.13	18.96	20.10	772
	Unchanged	23.61	29.94	31.21	1177
	Changed	1.70	1.99	2.09	132
	Recommendations	3.74	4.20	4.40	171

Performance of RadPhi-3 on Temporal Change Summary task. Low performance in Changed and Recommendations category can be attributed to less support.

Table 9: RaLEs Benchmark - Impression Prediction

Dataset	Metrics	Best Reported	RadPhi-3
MEDIQA-2021	Rouge 2	0.250	<b>0.271</b>
	RougeL	0.388	<b>0.409</b>
	Chexbert	<b>0.725</b>	0.697
	RG	<b>0.406</b>	0.353
BIONLP-2023	Rouge 2	0.189	<b>0.204</b>
	RougeL	0.303	<b>0.310</b>
	Chexbert	0.506	<b>0.564</b>
	RG	0.283	<b>0.325</b>
<b>NLG Score</b>		0.345	<b>0.349</b>

Table 10: Padchest Label Metrics (Spanish Reports)

Metric	Score
F1-score	97.64 [97.51, 97.71]
Precision	97.79 [97.67, 97.88]
Recall	97.9 [97.78, 97.96]

## Appendix B. Dataset Statistics

Table 11: Temporal Change Summary Metrics - RadGraph2

Change Category	Progression	BLEU-4	RougeL	F1-Score	Support
Medical conditions and devices	Stable	86.30	81.60	93.99	77
	Improved	83.61	81.85	89.09	13
Medical conditions	Worsened	81.18	79.13	86.61	21
	New	70.45	72.13	77.99	8
	Resolved	36.46	43.08	46.71	1
Medical devices	Removed	87.56	90.94	96.43	7
	New	43.13	52.13	55.17	5
	Advanced	82.76	85.19	88.25	2

Performance of RadPhi-3 on Temporal Change Summary task. Low performance on Resolved category due to very less support.

Table 12: Radiology Question Answering Dataset Statistics (Radiopaedia.org)

Systems	Article Counts	Summary Counts	QA Pair Counts
Chest	1710	31	9695
Cardiac	767	4	5188
Central Nervous System	2817	29	16557
Urogenital	703	2	4171
Oncology	391	0	2782
Breast	356	1	1929
Musculoskeletal	3758	46	24026
Not Specified	1579	0	10880
Hepatobiliary	469	1	2956
Vascular	420	3	2304
Gastrointestinal	1210	30	7342
Obstetrics	568	0	3157
Interventional	149	0	1003
Trauma	85	0	483
Spine	94	0	490
Forensic	17	1	105
<b>Total</b>	15076	148	93068

Table 13: Radiology Report Task Dataset Statistics

Task	Train	Test	Validation
Impression Prediction	208,876	2,523	1,647
Cleanup Radiology Text	50,000	9,337	5,549
Abnormality Labels	221,035	3,403	1,959
QA Comprehension	467,057	9,179	3,878
Extract Findings	50,000	3,844	2,103
Tubes, Lines and Devices Labels	94,915	3,403	1,959
Extract Impression	50,000	3,283	2,295
RadNLI, MEDNLI	11,712	1,902	1,395
Radiology Report Segmentation	282,592	-	308
Impression Prediction (Chexpert Plus)	59,364	-	74
Temporal Change Summary	151667	2,817	1,259

Table 14: Benchmark Dataset Statistics

Dataset	Train	Test	Validation
BioNLP-2023 (RaLEs)	59,320	6,526	7,413
MEDIQA-2021 (RaLEs)	91,544	600	2,000
Temporal Change Summary (Radgraph-2)	227,643	150	75
Padchest Label Prediction	137,221	7,872	15,665

Table 15: Temporal Change Summary Statistics - RadGraph2

Change Summary	Progression	Train	Test	Validation
Medical conditions and devices	Stable	381	77	47
	Improved	86	13	15
	Worsened	127	21	17
Medical conditions	New	49	8	3
	Resolved	16	1	2
	Removed	33	7	6
Medical devices	New	17	5	3
	Advanced	13	2	1

Table 16: CheXpert Plus Section Statistics

Section	Train	Validation
Comparison	212,845	228
Impression	223,083	234
Summary	189,455	193
Clinical History	176,871	175
Finding	59,395	74
Procedure Comments	25,637	32
Technique	10,719	13
End of Impression	7,385	7
Total Records	282,592	308

Table 17: Temporal Change Summary - Mimic CXR

Summary Category	Labels	Train	Test	Validation
	Stable	303,689	6,150	2,604
	Resolved	68,939	1,323	589
	Negatives	222,780	4,102	1,848
Diseases Change_Summary	Worsened	40,827	864	340
	New	116,147	2,409	970
	Improved	34,318	683	284
	Removed	51,738	1,029	432
	Unchanged	69,263	1,554	642
Tube.Lines Change_Summary	New	49,940	1,077	441
	Recommendations	10,110	183	91
	Changed	9,637	141	77

## Appendix C. Stratified Metrics

Table 18: System Wise Metrics for Radiology Question Answering on Radiopaedia Summary Articles.

System	Metrics	Phi-3-mini-4k-instruct	RadPhi-2	GPT-4	RadPhi-3
Chest	F1-Score	35.08 [34.24, 36.12]	<b>39.64</b> [37.68, 41.64]	36.73 [35.39, 37.04]	39.57 [37.9, 41.1]
	Precision	22.87 [21.81, 23.47]	42.76 [40.56, 45.37]	32.41 [30.62, 33.62]	<b>44.68</b> [43.29, 46.55]
	Recall	<b>75.22</b> [74.43, 76.54]	36.95 [34.67, 39.66]	42.37 [40.13, 43.81]	35.51 [34.09, 37.89]
	RougeL	12.33 [11.55, 12.69]	26.83 [25.33, 28.54]	24.65 [23.86, 25.54]	<b>28.38</b> [26.99, 29.94]
Cardiac	F1-Score	34.01 [31.09, 36.71]	<b>35.69</b> [31.37, 41.0]	33.78 [30.29, 37.11]	35.34 [33.47, 39.86]
	Precision	21.92 [20.87, 23.39]	35.8 [30.59, 39.75]	28.5 [25.48, 33.13]	<b>40.91</b> [35.7, 44.57]
	Recall	<b>75.94</b> [71.1, 81.18]	35.59 [33.01, 41.29]	41.45 [36.92, 43.22]	31.1 [27.64, 34.39]
	RougeL	11.48 [9.69, 12.88]	19.57 [17.97, 23.44]	20.23 [17.69, 22.23]	<b>22.41</b> [20.28, 24.11]
Gastrointestinal	F1-Score	33.51 [32.68, 34.56]	37.78 [35.85, 38.88]	32.93 [31.99, 33.66]	<b>38.95</b> [37.77, 40.14]
	Precision	21.61 [21.31, 23.06]	40.13 [38.07, 42.2]	27.89 [26.4, 28.75]	<b>42.85</b> [41.3, 43.95]
	Recall	<b>74.58</b> [73.23, 75.98]	35.69 [34.2, 38.42]	40.19 [38.34, 41.73]	35.71 [34.24, 37.8]
	RougeL	11.98 [11.61, 12.74]	24.23 [22.85, 25.44]	22.45 [21.56, 23.01]	<b>26.91</b> [25.8, 28.44]
Musculoskeletal	F1-Score	33.55 [32.86, 35.07]	40.11 [39.05, 41.79]	36.5 [34.89, 37.83]	<b>40.84</b> [39.51, 42.38]
	Precision	21.47 [20.92, 22.39]	43.19 [42.14, 44.48]	31.21 [30.12, 32.56]	<b>44.43</b> [43.59, 46.67]
	Recall	<b>76.77</b> [74.78, 77.8]	37.43 [35.74, 38.19]	43.96 [42.4, 45.4]	37.78 [36.29, 39.3]
	RougeL	12.49 [12.05, 12.95]	29.67 [29.13, 30.21]	26.54 [25.81, 27.16]	<b>30.18</b> [29.34, 31.86]
Central Nervous System	F1-Score	34.18 [32.87, 34.51]	36.62 [35.55, 37.8]	33.46 [31.95, 34.96]	<b>37.65</b> [36.1, 40.25]
	Precision	22.08 [21.01, 22.83]	41.13 [39.76, 42.61]	29.46 [28.19, 31.33]	<b>41.07</b> [39.27, 43.37]
	Recall	<b>75.58</b> [73.95, 76.39]	33.01 [30.63, 34.1]	38.72 [36.46, 40.25]	34.74 [32.79, 37.83]
	RougeL	11.58 [10.97, 12.17]	25.41 [23.82, 26.16]	22.37 [21.04, 23.27]	<b>24.95</b> [23.94, 26.68]
Breast	F1-Score	31.02 [28.96, 32.34]	44.99 [41.83, 49.87]	36.42 [31.85, 42.53]	<b>45.39</b> [34.85, 49.99]
	Precision	19.26 [17.61, 20.71]	43.87 [38.35, 62.14]	29.93 [26.63, 32.68]	<b>45.08</b> [38.27, 50.59]
	Recall	<b>79.64</b> [75.53, 82.85]	46.18 [35.35, 54.97]	46.52 [39.93, 51.5]	45.7 [41.12, 53.0]
	RougeL	9.11 [8.41, 9.84]	27.99 [22.04, 38.85]	25.09 [22.12, 28.86]	<b>32.92</b> [29.25, 39.1]
Urogenital	F1-Score	33.97 [31.68, 36.49]	38.38 [36.1, 41.82]	34.14 [30.74, 37.34]	<b>40.55</b> [36.93, 44.36]
	Precision	21.5 [19.96, 22.91]	40.76 [37.62, 46.24]	28.26 [24.71, 29.36]	<b>41.81</b> [36.55, 44.33]
	Recall	<b>80.94</b> [77.25, 82.03]	36.27 [29.97, 39.91]	43.11 [34.54, 46.95]	39.36 [35.77, 45.5]
	RougeL	10.13 [9.32, 11.0]	26.95 [24.36, 30.56]	21.86 [18.85, 22.79]	<b>27.78</b> [23.7, 30.27]
Vascular	F1-Score	28.9 [28.1, 31.06]	34.66 [30.18, 40.45]	33.53 [29.83, 38.82]	<b>39.15</b> [37.03, 44.21]
	Precision	17.85 [14.67, 19.32]	34.55 [34.37, 38.27]	27.27 [23.98, 30.64]	<b>38.58</b> [29.55, 47.74]
	Recall	<b>75.88</b> [72.83, 77.13]	34.77 [33.26, 38.84]	43.52 [41.04, 50.72]	39.74 [34.97, 47.79]
	RougeL	9.84 [8.26, 11.48]	23.42 [21.51, 26.46]	21.97 [19.85, 25.3]	<b>24.75</b> [19.9, 33.26]
Forensic	F1-Score	27.41 [24.09, 32.25]	44.99 [38.99, 50.29]	32.32 [25.5, 36.49]	<b>49.25</b> [41.88, 57.61]
	Precision	16.75 [14.17, 19.99]	46.27 [38.47, 58.28]	24.38 [20.13, 32.99]	<b>48.72</b> [37.22, 54.07]
	Recall	<b>75.41</b> [69.56, 85.01]	43.78 [38.14, 47.7]	47.95 [37.47, 59.6]	49.79 [42.04, 56.95]
	RougeL	11.54 [7.15, 15.12]	43.52 [34.16, 50.44]	28.62 [20.44, 42.75]	<b>38.43</b> [32.25, 43.37]
Hepatobiliary	F1-Score	<b>37.51</b> [36.44, 40.21]	36.9 [30.59, 44.76]	29.94 [28.47, 34.41]	36.57 [30.16, 41.52]
	Precision	24.83 [20.98, 26.59]	<b>41.25</b> [33.54, 48.13]	27.48 [26.11, 31.82]	39.01 [32.36, 39.77]
	Recall	<b>76.62</b> [72.71, 80.57]	33.38 [23.55, 46.46]	32.89 [26.1, 46.39]	34.43 [30.27, 39.71]
	RougeL	13.45 [10.62, 14.65]	22.51 [19.43, 26.85]	23.02 [18.83, 27.28]	<b>27.15</b> [20.53, 30.1]

## Appendix D. Examples

Table 19: Abnormality Label Prediction Example

Prompt	Given the below radiology report: PREAMBLE: PA AND LATERAL VIEWS OF THE CHEST INDICATION: Shortness of breath , wheezing on exam. The right hemidiaphragm is elevated. Aside from linear atelectasis in the right base, the lungs are clear. There is no pneumothorax or pleural effusion. Cardiomedastinal contours are normal. The sternal wires are aligned. IMPRESSION: No evidence of acute cardiopulmonary abnormalities. What abnormality labels can be applied to these findings?
Ground Truth	atelectasis, linear/patchy atelectasis, lung opacity, elevated hemidiaphragm
RadPhi-3	atelectasis, linear/patchy atelectasis, lung opacity, elevated hemidiaphragm



Table 20: QA Comprehension Example

Prompt	Use the information from the radiology report below to answer the question that follows: PREAMBLE: PORTABLE CHEST, - COMPARISON: - study. FINDINGS: The patient is status post median sternotomy and coronary bypass surgery. Heart remains enlarged, and is accompanied by pulmonary vascular congestion. Interval improved aeration at both lung bases with improving atelectasis and decreasing pleural effusions. No new areas of consolidation within either lung. what level is the pleural effusion?
Ground Truth	decreasing
Phi3-mini-4k-instruct	The pleural effusion is described as decreasing, which implies that it is present but is lessening in severity. However, the report does not specify the exact level of the pleural effusion. To determine the level, a radiologist would typically look for the lowest point of the fluid collection on a chest X-ray or CT scan. Since the report does not provide a specific location, it is not possible to give a precise level without additional imaging details.
RadPhi-2	decreasing
RadPhi-3	decreasing

Table 21: Radiology Question Answering Example

Prompt	What is the epidemiology of abdominal aortic aneurysm?
Ground Truth	The prevalence of rupture increases with age, males are more commonly affected than females, prevalence is almost 10% in people over 65 years old, and it is the 10th commonest cause of death in Western populations.
Phi-3-mini-4k-instruct	Abdominal aortic aneurysm (AAA) is a localized enlargement of the abdominal aorta such that the diameter is greater than 3 cm or more than 50% larger than normal diameter. The epidemiology of AAA varies by region, but it is more common in men than in women, with a male-to-female ratio of approximately 4:1. The prevalence increases with age, with the majority of cases occurring in individuals over the age of 65. Smoking is a significant risk factor, and the prevalence of AAA is higher in smokers compared to non-smokers. Other risk factors include hypertension, atherosclerosis, family history of AAA, and male gender. The incidence of AAA is estimated to be about 2 to 4 per 1000 person-years in the general population. In some countries, such as the United Kingdom, screening programs for AAA have been implemented, which have led to increased detection rate.
GPT-4	The epidemiology of abdominal aortic aneurysm (AAA) shows a prevalence of around 2-8% among older adults, especially in men over 65. Risks include age, smoking, hypertension, and a family history of AAA. Incidence is declining due to decreased smoking rates and improved hypertension control.
RadPhi-3	Abdominal aortic aneurysms are more common in men than in women. The prevalence increases with age, and the majority of aneurysms are diagnosed in patients over 65 years of age.

Table 22: Padchest Label Prediction Example

Prompt	Considerando el siguiente informe radiol'ogico, cambi pulmonar cronic con tract fibros lsd . aumnt densid parec extrapleural call osea fals imag nivel medi hemitorax derech . cit complet estudi con tc torax . ¿ cu'ales son las posibles anomal'ias o etiquetas de dispositivos para los hallazgos en el informe radiol'ogico ?
Ground Truth	increased density, fibrotic band, chronic changes
RadPhi-3	chronic changes, fibrotic band, increased density

Table 23: Impression Prediction Example

Prompt	<p>Given the findings from a radiology report:  An extensive right hilar lung mass is associated with radiation fibrosis, better delineated on CT .. An additional component of postobstructive pneumonia may be present. Retrocardiac opacity, left pleural effusion, and left plueral thickening are also new. No pneumothorax is present.  The findings from the radiology report above need an impression. Write one.</p>
Ground Truth	<p>Large right hilar lung mass and radiation fibrosis are present. There is an opacity in the left retrocardiac region. There is a small left effusion and thickening of the pleura.</p>
Phi-3-mini-4k-instruct	<p>The patient presents with a significant right hilar mass suggestive of a neoplastic process, likely secondary to prior radiation therapy, as indicated by the presence of radiation fibrosis. The mass is more clearly defined on CT imaging. There is also a suspicion of postobstructive pneumonia, which may be contributing to the patient’s respiratory symptoms. New findings include a retrocardiac opacity, which could represent a mass or consolidation, a left pleural effusion, and left pleural thickening. These findings warrant further investigation, including a possible biopsy of the hilar mass and evaluation of the pleural effusion. No evidence of pneumothorax is noted.</p>
RadPhi2	<p>Right hilar mass is present. There is a component of postobstructive pneumonia. Left lower lobe opacity is present, likely due to a combination of pleural effusion and atelectasis.</p>
RadPhi-3	<p>Right hilar mass is present. There is radiation fibrosis. There is a left lower lobe pneumonia. There is a left pleural effusion.</p>

Table 24: Cleanup Radiology Text Example

Prompt	<p>Given the findings from a radiology report:  The cardiomediastinal and hilar silhouettes remain stable. There are bilateral upper lung reticular and nodular opacities with associated volume loss, stable compared to the prior study. The lungs are otherwise clear with no focal consolidation. There is no pleural effusion, pulmonary edema, or pneumothorax. The osseous structures are unremarkable.  Update the findings such that each sentence in the output describes a finding or observation about the image. Remove any mention of change of an observation and just state its presence. Do not include any follow-up suggestions or advice, and avoid mentioning any doctor names or other noisy details.</p>
Ground Truth	<p>There are bilateral upper lung reticular and nodular opacities with associated volume loss. The lungs are otherwise clear with no focal consolidation. There is no pleural effusion, pulmonary edema, or pneumothorax. The osseous structures are unremarkable.</p>
RadPhi-2	<p>Bilateral upper lung reticular and nodular opacities with associated volume loss are present. The lungs are clear with no focal consolidation. There is no pleural effusion, pulmonary edema, or pneumothorax. The osseous structures are unremarkable.</p>
RadPhi-3	<p>Bilateral upper lung reticular and nodular opacities with associated volume loss are present. The lungs are clear with no focal consolidation. There is no pleural effusion, pulmonary edema, or pneumothorax. The osseous structures are unremarkable.</p>

Table 25: Impression Extraction Example

Prompt	<p>Given the radiology report below:</p> <p>INDICATION: History of sarcoidosis, now status post laparoscopic Nissen on post-op day # 2 with respiratory desaturations, here to evaluate for recurrent pneumonia.</p> <p>COMPARISON: Chest radiograph, last performed on .</p> <p>TECHNIQUE: PA and lateral radiographs of the chest.</p> <p>FINDINGS: The inspiratory lung volumes are decreased from the most recent prior study. Increased opacification of the bilateral bases is likely reflective of atelectasis in the post-operative setting of low lung volumes. Prominent lung markings raise the possibility of chronic lung disease. Small bilateral pleural effusions are present. No pneumothorax is detected. The cardiac silhouette is likely within normal limits allowing for low lung volumes. No overt pulmonary edema is present. Calcified hilar and mediastinal lymph nodes are redemonstrated, compatible with sequela of known sarcoidosis. Multiple healed right posterior rib fractures are again noted.</p> <p>IMPRESSION: 1. Bibasilar opacities most likely represent atelectasis in the post-operative setting of low lung volumes. Small pleural effusions. 2. Stable calcified hilar and mediastinal lymph nodes compatible with known sarcoidosis. 3. Suggestion of chronic lung disease.</p> <p>Output the impression of the radiology report. Do not mention any doctor names, noisy details, or follow-up advice or changes in observations.</p>
Ground Truth	Bibasilar opacities most likely represent atelectasis. Small pleural effusions are present. Calcified hilar and mediastinal lymph nodes compatible with sarcoidosis. There is suggestion of chronic lung disease.
RadPhi-3	Bibasilar opacities are present, likely representing atelectasis in the post-operative setting of low lung volumes. Small pleural effusions are observed. Calcified hilar and mediastinal lymph nodes are present, compatible with known sarcoidosis. There is suggestion of chronic lung disease.

Table 26: Tubes, Lines and Device Label Prediction Example

Prompt	<p>Given the below radiology report:</p> <p>EXAMINATION: CHEST (PORTABLE AP)</p> <p>INDICATION: - year old man with very reduced EF, s/p Respiratory and PEA arrest and intubation - now with OG tube. // OG tube placement OG tube placement</p> <p>COMPARISON: Prior chest radiographs - through -.</p> <p>IMPRESSION: More dependent distribution of right pleural effusion is due to more positioning of the patient. Previously questioned new right upper lobe consolidation is smaller than assumed. Moderate cardiomegaly and pulmonary vascular congestion persist. There is probably minimal pulmonary edema. ET tube in standard placement. Right jugular line ends in the upper SVC. Nasogastric tube ends at the diaphragm and would need to be advanced at least 15 cm to move all side ports into the stomach.</p> <p>What are the tubes and lines or devices that are mentioned in the radiology report?</p>
Ground Truth	enteric tube, endotracheal tube, ij line
RadPhi-3	ij line, endotracheal tube, enteric tube

Table 27: NLI Example

Prompt	<p>In this task, you are given a premise and hypothesis.  The task is to classify them into three categories: 'positive' if the hypothesis supports the premise, 'negated' if it opposes the premise, and 'neutral' if it neither supports nor opposes it.  Premise: A recent TEE showed severe aortic stenosis with an aortic valve area of 0.7cm<sup>2</sup>.  Hypothesis: Patient has a normal echo</p>
Ground Truth	negated
RadPhi-3	negated

Table 28: RadGraph2 - Temporal Summary Example

Prompt	<p>Given a radiology report generate a change summary  Report:  FINAL REPORT CHEST RADIOGRAPH PERFORMED ON ___ COMPARISON : Prior exam from ___ . CLINICAL HISTORY : Cirrhosis with confusion , question pneumonia . FINDINGS : AP portable upright chest radiograph was provided . As seen previously , there are bilateral pleural effusions slightly increased on the left and stable on the right . The subjacent opacities in the lower lungs could represent atelectasis versus pneumonia . The upper lungs are well aerated . The cardiomeastinal silhouette is stable . Bony structures are intact . TIPS partially imaged in the right upper quadrant . IMPRESSION : Bilateral pleural effusions , subjacent consolidations , may represent atelectasis versus pneumonia .</p>
Ground Truth	<p>Change summary of medical devices:  Change summary of medical conditions:  Worsened:  As seen previously , there are bilateral pleural effusions slightly increased on the left and stable on the right .  No change summary:  Stable:  As seen previously , there are bilateral pleural effusions slightly increased on the left and stable on the right .  The cardiomeastinal silhouette is stable .</p>
RadPhi-3	<p>Change summary of medical devices:  Change summary of medical conditions:  Worsened:  As seen previously, there are bilateral pleural effusions slightly increased on the left and stable on the right.  No change summary:  Stable:  The cardiomeastinal silhouette is stable.  As seen previously, there are bilateral pleural effusions slightly increased on the left and stable on the right.</p>

Table 29: CheXpert Section Extraction Example

Prompt	<p>Given the radiology report below: NARRATIVE: RADIOGRAPHIC EXAMINATION OF THE CHEST: 2002 january 26th CLINICAL HISTORY: 53 years of age, Female, postop. COMPARISON: Same day radiograph PROCEDURE COMMENTS: Single view of the chest. FINDINGS: The transesophageal echo probe has been removed. A new enteric tube is present. There is otherwise unchanged positioning of supportive medical devices. Mild pulmonary edema and cardiomegaly. Left basilar opacity. No pneumothorax. No acute bony abnormalities are noted. IMPRESSION: 1. Residual mild pulmonary edema and left basilar opacity. "Physician to Physician Radiology Consult Line: (898) 940-4661" Signed          ACCESSION NUMBER: 04240392 This report has been anonymized. All dates are offset from the actual dates by a fixed interval associated with the patient.          Extract all the important sections from it for better interpretability.</p>
Ground Truth	<p>Clinical History:          53 years of age, Female, postop.          Comparison:          Same day radiograph          Technique:          N/A          Procedure Comments:          Single view of the chest.          Findings:          The transesophageal echo probe has been removed. A new enteric tube is present. There is otherwise unchanged positioning of supportive medical devices. Mild pulmonary edema and cardiomegaly. Left basilar opacity.No pneumothorax. No acute bony abnormalities are noted.          Impression:          1. Residual mild pulmonary edema and left basilar opacity."Physician to Physician Radiology Consult Line: (898) 940-4661"          Signed          End Of Impression:          N/A          Summary:          N/A</p>
RadPhi-3	<p>Clinical History:          53 years of age, Female, postop.          Comparison:          Same day radiograph          Technique:          N/A          Procedure Comments:          Single view of the chest.          Findings:          The transesophageal echo probe has been removed. A new enteric tube is present. There is otherwise unchanged positioning of supportive medical devices. Mild pulmonary edema and cardiomegaly. Left basilar opacity.No pneumothorax. No acute bony abnormalities are noted.          Impression:          1. Residual mild pulmonary edema and left basilar opacity."Physician to Physician Radiology Consult Line: (898) 940-4661"          Signed          End Of Impression:          N/A          Summary:          N/A</p>

Table 30: Temporal Summary Example

Prompt	<p>Given a current radiology report and a previous report of the same patient, generate a change summary Current Report: FINAL REPORT SINGLE AP PORTABLE VIEW OF THE CHEST REASON FOR EXAM: AVR, assess for occlusions. COMPARISON: Comparison is made with prior study of ---. Cardiomegaly is stable. Vascular congestion has improved, now is mild. Right lower lobe atelectasis has increased. Aeration of the left hemidiaphragm has minimally improved. Left IJ catheter tip is in the mid SVC. There is no evidence of pneumothorax. Small bilateral pleural effusions are unchanged. Previous Report: FINAL REPORT CHEST RADIOGRAPH TECHNIQUE: Single portable upright radiograph of the chest was compared with prior radiograph from ---. FINDINGS: Since prior radiograph from ---, the mediastinal drain tube has been removed. There is no pneumothorax. Both lung volumes are very low. Bilateral, right side more than left side, moderate pulmonary edema has improved. Widened cardiomeastinal silhouette is more than it was on ---; however, this appearance could be exacerbation from low lung volumes. Patient is status post median sternotomy with intact sternal sutures.</p>
Ground Truth	<p>Diseases_Change_Summary:  New:  Resolved:  Stable:      Cardiomegaly      Small bilateral pleural effusions  Improved:      Vascular congestion      Aeration of the left hemidiaphragm  Worsened:      Right lower lobe atelectasis  Negatives:      There is no evidence of pneumothorax  Tubes_Lines_Change_Summary:  New:      Left IJ catheter tip is in the mid SVC  Removed:  Unchanged:  Changed:  Recommendations:</p>
RadPhi-3	<p>Diseases_Change_Summary:  New:  Resolved:  Stable:      Cardiomegaly      Small bilateral pleural effusions  Improved:      Vascular congestion      Aeration of the left hemidiaphragm  Worsened:      Right lower lobe atelectasis  Negatives:      No evidence of pneumothorax  Tubes_Lines_Change_Summary:  New:      Left IJ catheter tip is in the mid SVC  Removed:      Mediastinal drain tube  Unchanged:  Changed:  Recommendations:</p>

## Appendix E. Prompts

### Prompt Design - Temporal Summary Extraction

Given a current radiology report and a previous report of the same patient, generate a change summary with the following details:

**Change Summary for Diseases:** List of new conditions reported in the current report that did not exist before or list of conditions that were existing before and which were either completely resolved, improved, worsened, or unchanged (stable), all according to the current report. Conditions are considered stable if they are mentioned as stable or unchanged in the current report. Resolved conditions should be explicitly mentioned as fully resolved or cleared in the current report, and it should not include conditions that are just absent in the current report. Improved conditions should be reported under improvements and not as resolved unless fully resolved. New conditions are the conditions newly mentioned in the current report which were not mentioned in the previous report. Improvement or worsened conditions should also be explicitly stated as such in the current report. Negative findings are extracted under the negative category. However, mentions like "there is no new consolidation" mean the condition is unchanged or stable. Extract the progression category as new/resolved/stable/worsened/improved/negative, along with the corresponding progression description. This section should not include the changes related to devices, tubes, or lines.

**Tubes and Lines Change Summary:** List of findings related to any devices, tubes, or lines in the patient's body. This could be a new device or a line introduced into the patient's body which was not present before, or it was present before but has been removed now, or the device is present in both cases but the position of the device or line may have changed or remained unchanged. To be reported as unchanged, the device or line should be mentioned in both reports and described as stable or unchanged in the current report. To be reported as changed, the device or line/tube should be mentioned in both reports, and its position should have changed according to the current report (this does not refer to a recommendation for change but to a change in the placement of the device compared to the previous report). Extract the placement category as new/removed/changed/stable, with the corresponding placement description of the device/line/tube in the body. If there are recommendations regarding device/line/tube placement, they should be extracted separately under recommendations. If any device/tube/line is mentioned as "in place" or "in standard placement," it just means that it is in the right position and should not be confused with the definition of stable or unchanged, which means that the device was mentioned in both reports and its position has not changed.

Extract in the following JSON format:

```
{
  "Diseases_Change_Summary": {
    "New": <List of Findings that are new according to the current report. They should not be present in the previous report. >or [],
    "Resolved": <List of Findings that are mentioned as fully resolved or cleared in the current report. >or [],
    "Stable": <List of Findings that are unchanged or stable according to the current report. >or [],
    "Improved": <List of Findings that have been explicitly reported as improved according to the current report. >or [],
    "Worsened": <List of Findings that have been explicitly reported as worsened according to the current report. >or [],
    "Negatives": <List of conditions mentioned negatively in the current report. >or []
  },
  "Tubes_Lines_Change_Summary": {
    "New": <List of placement descriptions of new devices in the body according to the current report. >or [],
    "Removed": <List of Devices/Lines that have been removed according to the current report. >or [],
    "Unchanged": <List of placement descriptions of devices in the body whose position is unchanged according to the current report. >or [],
    "Changed": <List of placement descriptions of devices in the body whose position has changed according to the current report. >or [],
    "Recommendations": <List of placement recommendations on the positioning of devices in the body. >or []
  }
}
```

If there are no extractions for a particular category, just return an empty list for that category. No findings should overlap across categories. Additionally, do not miss reporting any finding in the current report. It should be covered under one of the two section categories (do not include symptoms of the patient, but only radiographic findings with respect to the current report). The changes are written only with respect to findings and tube/line mentions in the current report. The previous report may also have changes with respect to its prior report, which should be ignored.

### Prompt Design - Cleanup Radiology Text

Given the below findings from a radiology report. Paraphrase the findings into individual sentences without mention of priors.  
{FINDINGS}

### Prompt Design - Radiopaedia Question Answering Dataset

Given a radiology article in an html format extract the content of the entire article as longform question and answer pairs using the format mentioned below. The article content is structured under various headings. Create question answer pair for every heading of the article framing the question using the heading and answer as the content under the heading. If there are sub-headings or bullet points, then create question answer pair for them as well if it cannot be included in the main heading. If there are descriptions as sub-bullet points include them as well. All content of the article should be included in one of the question answer pairs. The questions and answers should strictly be sourced from the article itself.

Question-Answer format: ["question": question from the article, "answer": answer from the article]

Table 31: Prompt Design - Instruction Tuning Dataset for Radiology Reports.

Source	Task Name	Prompt
Mimic-CXR	Findings/Impression Extraction	Given the radiology report below: FULL REPORT Output the findings/impression of the radiology report. Each sentence in the output should describe an observation or a finding about the image. Do not mention any changes in observations, follow-up suggestions, doctor names, or noisy details.
Mimic-CXR	Cleanup Report Text	Given the text from a radiology report: RADIOLOGY REPORT TEXT Update the impressions or findings such that each sentence in the output describes an impression or observation about the image. Remove any mention of change of an observation and just state its presence. Do not include any follow-up suggestions or advice, and avoid mentioning any doctor names or other noisy details.
Mimic-CXR	Impression Prediction	Given the findings from a radiology report: FINDINGS Based on the above findings from a radiology report, write an impression.
Chest-Imagenome	Abnormality Labels	Given the below radiology report: FULL REPORT What abnormality labels can be tagged to these findings?
Medical-Diff-VQA	QA Comprehension	Answer the question using the radiology report below as context: FULL REPORT Question:
CheXpert Plus	CheXpert Section Extraction	Given the radiology report below: REPORT TEXT Extract all the important sections from it for better interpretability.
Mimic-CXR	Temporal Summary	Given a current radiology report and a previous report of the same patient, generate a change summary. Current Report: CURRENT_REPORT Previous Report: PREVIOUS_REPORT
MedNLI & RadNLI	Natural Language Inference	In this task, you are given a premise and hypothesis. The task is to classify them into three categories: 'positive' if the hypothesis supports the premise, 'negated' if it opposes the premise, and 'neutral' if it neither supports nor opposes it. Premise: Hypothesis:
Chest-Imagenome	Tubes, Lines and Devices Labels	Given the below radiology report: FULL_REPORT The radiology report above has some tubes and lines or devices. What are they?
Padchest	Label Prediction	Considerando el siguiente informe radiológico, FULL_REPORT ¿cuáles son las posibles anomalías o etiquetas de dispositivos para los hallazgos en el informe radiológico ?



## Appendix F. Generalization to New Tasks - Examples

Table 32: Temporal Sentence Similarity Task - MS-CXR-T Example-1

Prompt	You are a radiologist. Assess whether two sentences are describing the same meaning (paraphrase) or different meaning (different) regarding the change information. Reply with paraphrase or different - - INPUT Sentence1: right mid lung opacity has slightly improved. Sentence2: right mid lung opacity has slightly worsened. ANSWER:
Ground Truth	different
Phi3-mini-4k-instruct	different
Rad-Phi2-Instruct	improved
Rad-Phi3-Instruct	different

Table 33: Temporal Sentence Similarity Task - MS-CXR-T Example-2

Prompt	You are a radiologist. Assess whether two sentences are describing the same meaning (paraphrase) or different meaning (different) regarding the change information. Reply with paraphrase or different. - - INPUT Sentence1: status post right thoracentesis with interval decrease in right pleural effusion, which is now trace in size. Sentence2: status post right thoracentesis with interval increase in right pleural effusion, which is now trace in size. ANSWER:
Ground Truth	different
Phi3-mini-4k-instruct	different
Rad-Phi2-Instruct	no
Rad-Phi3-Instruct	different

Table 34: RAD-QA Dataset example

Prompt	<p>Given below the question: Are there any changes in the diffuse convalescent opacities in the lungs? and the radiology report: FINAL REPORT INDICATION: Neutropenia and Pneumocystis pneumonia. CHEST X-RAY, PORTABLE AP: COMPARISON: - Endotracheal tube is properly positioned with the tip at the thoracic inlet. A left subclavian central venous line is again demonstrated with tip in the mid- superior vena cava. No pneumothorax. There has been interval improvement in the bilateral ground glass, patchy opacities. Nasogastric tube is also seen properly positioned in the stomach. Extract the full sentence from the report that can answer the question. Don't answer the question, just extract the part of the radiology report which can answer the question. If there is no sentence that can be used to answer the question return Not possible to extract.</p>
Ground Truth	improvement in the bilateral ground glass, patchy opacities
Phi3-mini-4k-instruct	There has been interval improvement in the bilateral ground glass, patchy opacities.
RadPhi2-Instruct	The endotracheal tube is properly positioned with the tip at the thoracic inlet. A left subclavian central venous line is demonstrated with tip in the mid- superior vena cava. No pneumothorax is present. Bilateral ground glass, patchy opacities are seen. The nasogastric tube is properly positioned in the stomach.
RadPhi-3	There has been interval improvement in the bilateral ground glass, patchy opacities.

Table 35: Extraction of Tubes and Lines Placement Information

Prompt	<p>Given the below radiology report: PREAMBLE: SINGLE FRONTAL VIEW OF THE CHEST INDICATION: Respiratory failure. LAST_PARAGRAPH: Comparison is made with prior study, .. Cardiac size is normal. Large right and moderate left pleural effusions are grossly unchanged allowing for differences in positioning of the patient. NG tubes are in the stomach. ET tube is in the standard position. Right peripherally inserted catheter tip is in the right subclavian vein, unchanged. Output the full placement description of the devices mentioned in the report. If no device is mentioned return N/A.</p>
Ground Truth	NG tubes are in the stomach. ET tube is in the standard position. Right peripherally inserted catheter tip is in the right subclavian vein.
Phi3-mini-4k-instruct	N/A Explanation: The radiology report does not mention any specific devices that are placed within the patient's body. It only mentions the presence of NG (nasogastric) tubes in the stomach and an ET (endotracheal) tube in the standard position, but these are not considered devices that are placed for the purpose of the radiological examination.
RadPhi2-Instruct	NG tubes are in the stomach. ET tube is in the standard position. Right peripherally inserted catheter tip is in the right subclavian vein.
RadPhi-3	NG tube is in the stomach. ET tube is in the standard position. Right peripherally inserted catheter tip is in the right subclavian vein.

## Appendix G. Hallucination Measurements

Table 36: Align Score Metric for Dataset Creation - Radiology QA Dataset

<b>Task</b>	<b>Align Score Mean</b>	<b>Align Score Median</b>
Radiopaedia QA-Pairs using GPT-4	0.89 ± 0.10	0.92

The alignment score metrics for the Radiology QA dataset with respect to the Radiopaedia articles are very high, indicating that GPT-4 didn't hallucinate while creating the dataset.

Table 37: Radiologist Evaluation - Radiology QA Dataset Error Counts

<b>Article Count</b>	<b>Hallucination of Facts</b>	<b>Instruction-following Hallucination</b>	<b>Quality Errors</b>
82	0	1	5

Error counts for the Radiology QA Dataset created by GPT-4. Hallucination of facts refers to errors related to facts in the answers that were not present in the article. Instruction-following hallucinations refer to inadequate adherence to instructions while answering a question. Quality errors refer to question-answer pairs that are not very useful in a clinical setting.

Table 38: Radiologist Evaluation - Temporal Summary Dataset Error Counts

<b>No of Temporal Extractions</b>	<b>Hallucination of Facts</b>	<b>Hallucination of Category</b>	<b>Missed Findings</b>
50	0	5	7

Error counts for the Temporal Summary Dataset created by GPT-4. Hallucination of facts refers to errors related to facts in the answers that were not present in the current or prior report. Hallucination of category refers to errors where the change summary category (new, improved, worsened, resolved, etc.) was incorrectly assigned. Missed findings errors are related to the missed change mentions.

Table 39: Radiologist Evaluation - Impression Prediction

<b>No. of Findings</b>	<b>Missed Findings</b>	<b>False Findings</b>	<b>Position Errors</b>	<b>Severity Errors</b>
149	14	1	2	0

Error counts by category for the impression prediction task. The errors were mostly related to the findings missed in the predictions. The 149 findings were associated with 50 impressions.

Table 40: Radiologist Feedback Example - Temporal Change Summary Dataset

<p>Prompt</p>	<p>Given a current radiology report and a previous report of the same patient, generate a change summary                  Current Report: FINAL REPORT EXAMINATION: CHEST (PORTABLE AP)                  INDICATION: _ year old man with ventilator dependence interval scan ?CXR CHANGES                  IMPRESSION:                  Compared to chest radiographs _ through _.                  Bibasilar atelectasis, severe on the right, moderate on the left, unchanged since earlier on _.                  Moderate right pleural effusion is probably present. There is no pulmonary edema although pulmonary vasculature is mildly engorged. No pneumothorax.                  Cardiopulmonary support devices in standard placements.                  Previous Report: FINAL REPORT EXAMINATION: CHEST (PORTABLE AP)                  INDICATION: _ year old man with Right-sided occipital craniotomy for evacuation. interval change                  TECHNIQUE: Single frontal view of the chest                  COMPARISON: _                  IMPRESSION:                  Cardiomediastinal contours are unchanged. Moderate right pleural effusion has increased with associated adjacent atelectasis. Mild vascular congestion has increased. ET tube is in standard position. Right subclavian catheter tip is in the lower SVC. NG tube tip is out of view below the diaphragm</p>
<p>GPT-4</p>	<p>Diseases_Change_Summary:                  New:                  Resolved:                  Stable:                  Bibasilar atelectasis, severe on the right, moderate on the left Moderate right pleural effusion No pulmonary edema Pulmonary vasculature is mildly engorged                  Improved:                  Worsened:                  Negatives:                  No pneumothorax                  Tubes_Lines_Change_Summary:                  New:                  Removed:                  ET tube Right subclavian catheter NG tube                  Unchanged:                  Changed:                  Recommendations:</p>
<p>Radiologist Feedback</p>	<p>The devices are not removed, all of them have been captured as ‘Cardiopulmonary support devices in standard placements’.</p>

Table 41: Radiologist Feedback Example - Radiology QA Dataset

Question	What are the different panda signs?
Answer Generated by GPT-4 using the <a href="#">Radiopaedia Article</a>	<ol style="list-style-type: none"> <li>1. panda sign of the midbrain,</li> <li>2. double panda sign,</li> <li>3. panda sign of sarcoidosis,</li> <li>4. panda eyes (base of skull fracture)</li> </ol>
Radiologist Feedback	<p>The Radiopaedia article didn't have enough content to answer this question. The actual answer should contain more details like the below: Panda sign are present in various following pathology and seen under various investigation search:</p> <ol style="list-style-type: none"> <li>1. sarcoidosis: under 67 gallium scan denoting uptake of it by lacrimal and parotid gland</li> <li>2.panda eyes : seen in fracture of anterior of anterior cranial fossa ( dark coloured area around the eyes)</li> <li>3.double panda sign: t2 mri indicating Wilson dis</li> <li>4.panda sign of mid brain: t2 mri indication of Wilson dis</li> </ol>

Table 42: Radiologist Feedback Example - Radiology QA Dataset

Question	What is the treatment and prognosis for cystic nephromas?
Answer Generated by GPT-4 using the <a href="#">Radiopaedia Article</a>	Radical or partial nephrectomy is usually done, with lymph node excision
Radiologist Feedback	The model has answered about treatment but not the prognosis. The Radiopaedia article did not contain the prognosis.

Table 43: Radiologist Feedback Example - Radiology QA Dataset

Question-Answer Generated by GPT-4 using the <a href="#">Radiopaedia Article</a>	<pre>[ 'question': 'What are the mnemonics for hepatic capsular retraction?', 'answer': 'CT CHIEF, FILTH E, and FITCH are mnemonics for hepatic capsular retraction.', 'question': 'What does CT CHIEF stand for?', 'answer': 'C: cholangiocarcinoma (intrahepatic), T: treated hepatic metastasis or hepatocellular carcinoma, C: cirrhosis with confluent hepatic fibrosis, H: hemangioma (especially sclerosed hepatic hemangioma), I: inflammatory pseudotumor, hepatic, E: epithelioid hemangioendothelioma, F: fibrolamellar hepatocellular carcinoma.', 'question': 'What does FILTH E stand for?', 'answer': 'F: fibrosis in confluent hepatic fibrosis, I: intrahepatic cholangiocarcinoma, L: lamellar as in fibrolamellar hepatocellular carcinoma, T: treated metastasis, H: hepatocellular carcinoma (uncommon manifestation), E: epithelioid hemangioendothelioma.', 'question': 'What does FITCH stand for?', 'answer': 'F: fibrolamellar hepatocellular carcinoma, I: inflammatory pseudotumor, hepatic, T: treated hepatic metastasis or hepatocellular carcinoma, C: cholangiocarcinoma, confluent hepatic fibrosis, H: hemangioma, hemangioendothelioma.']</pre>
Radiologist Feedback	Question-Answer pairs should be more clinically useful, this one is just abbreviations.